

B-Cure Laser Dental Pro technology for prevention and treatment of peri-implant mucositis

O. S. Gileva, T. V. Libik, M. A. Chuprakov, A. Y. Yakov, and F. Z. Mirsaeva

Citation: [AIP Conference Proceedings](#) **1882**, 020021 (2017);

View online: <https://doi.org/10.1063/1.5001600>

View Table of Contents: <http://aip.scitation.org/toc/apc/1882/1>

Published by the [American Institute of Physics](#)

Articles you may be interested in

[Management of cancer therapy-induced oral mucositis pain and xerostomia with extra- and intra oral laser irradiation](#)

AIP Conference Proceedings **1882**, 020044 (2017); 10.1063/1.5001623

[Abnormal behavior of ZrO₂-MgO porous ceramic composite under compression](#)

AIP Conference Proceedings **1882**, 020010 (2017); 10.1063/1.5001589

[Nanostructures based on alumina hydroxides inhibit tumor growth](#)

AIP Conference Proceedings **1882**, 020019 (2017); 10.1063/1.5001598

[Nanomaterials potentiating standard chemotherapy drugs' effect](#)

AIP Conference Proceedings **1882**, 020031 (2017); 10.1063/1.5001610

[Application of nanodimensional particles and aluminum hydroxide nanostructures for cancer diagnosis and therapy](#)

AIP Conference Proceedings **1882**, 020036 (2017); 10.1063/1.5001615

[Surface modification of polylactic acid films by atmospheric pressure plasma treatment](#)

AIP Conference Proceedings **1882**, 020037 (2017); 10.1063/1.5001616

B-Cure Laser Dental Pro Technology for Prevention and Treatment of Peri-Implant Mucositis

O. S. Gileva^{1,a)}, T. V. Libik^{1,b)}, M. A. Chuprakov^{1,2}, A. Y. Yakov¹,
and F. Z. Mirsaeva³

¹ Perm State Medical University named after academician E.A. Wagner, Perm, Russia

² Perm Municipal Dental Clinic No. 2, Perm, Russia

³ Bashkir State Medical University, Ufa, Russia

^{a)} Corresponding author: ogileva@rambler.ru

^{b)} libiktat@yandex.ru

Abstract. Oral mucositis (OM) is the severe inflammation, lesioning and ulceration of the epithelia, accompanied by bleeding and intensive pain. OM is a common complication of dental implantation. Low-level laser therapy (LLLT) has been found to enhance the repair and healing of epithelia. The aim of this study was to evaluate the effectiveness of preventive and treatment use of LLLT (B-Cure Laser Dental Pro technology in original author's techniques) in the patients who have undergone dental implantation. Simple blind randomized prospective one-center comparative placebo-controlled clinical trial is carried out on the group of 30 partially edentulous patients. It is proved that the use of LLLT before and after installation of dental implants provides: 1) reliable reduction (by 3.5 times) of the frequency of implication and intensity of pain in the first days after operation; 2) reduction (by 3.3–3.7 times) of frequency, duration and intensity of local edematous and inflammatory processes in peri-implant zone and facial soft tissue edema; 3) effective prophylaxis of postoperative sensory, paresthesia and neurologic disturbances in maxillofacial area.

BACKGROUND

In recent years, dental implants confidently retain the status of a leading trend in modern dentistry, making a serious alternative to the traditional techniques of fixed and removable prosthetics of dental defects, providing high aesthetic and functional results and improving the quality of life of the dental patient [1–4]. However, the possibility of early and late postoperative complications of dental implantation (DI) not entirely eliminated and may reduce the success of implant treatment, and therefore it requires adequate prevention, early detection and correction [5–9]. For the prevention and treatment of inflammatory and sensory-paresthetic complications of DI low-level laser therapy (LLLT) having multifactorial local and systemic effects on the patient [10–19] is reasonably used. However, the assessment of the impact of different methods of LLLT in the course of postoperative period of DI should be based on the modern principles of evidence-based medicine [20]. Improvement of LLLT technologies in DI is on the path of development of the so-called “optimized” laser effects, suggesting the possibility of variation of the mode, wavelength, power and the spatial distribution of the radiation; its combination with other physical factors; professional application by a doctor in a dental office or (and) by the patient at home. Multipurpose LLLT domestic portable devices such as “Geska-U” [21], “Duna-T” [22] and others have been used in medical practice for more than 10 years. However, in this study we opted the portable LLLT device B-Cure Laser Dental Pro that was specially developed for use in dental practice (defocused beam—1 cm × 4.5 cm—corresponding to the size of the dentoalveolar segment). Possible applications in the dental practice of the new portable diode laser device on the basis of Ga-Al-As infrared radiation band defocused beam (wavelength—808 nm, power—250 mW) B-Cure Laser Dental Pro (Good Energies ®, Israel) are not studied and limited with assessing of the clinical effectiveness in treatment of temporomandibular joint (TMJ) diseases [23].

The aim of the study—to justify, to develop a methodology and to evaluate the effectiveness of LLLT technology B-Cure Laser Dental Pro in a complex of preventive and medical rehabilitation of partially edentulous patients on stages of prosthetic treatment using dental implants.

MATERIALS AND METHODS

Single-blind randomized prospective single-center comparative placebo-controlled clinical trial to study the efficacy of LLLT by defocused beam of B-Cure Laser Dental Pro device in the complex events of the surgical phase of DI in prosthetic treatment of patients with partial edentulism was held in the period from June to October 2016 on the bases of SBEH PR “Municipal dental clinic No. 2” and the department of therapeutic and preclinic dentistry of FSBEI PGMU n.a. Academician E.A. Vagner of Ministry of Health Care of the Russian Federation (Perm).

Study inclusion criteria for patients: the presence of partial edentulism (partial loss of teeth; K08.1 according to ICD-10); age from 25 to 60 years; sanitized oral cavity and satisfactory oral hygiene; lack of contraindications for DI and LLLT; informed consent for treatment using DI and LLLT as well as for participation in this study. *Study exclusion criteria*: presence of systemic, local or other contraindications for DI and LLLT; age younger than 25 and older than 60 years; the lack of agreement for treatment using DI as well as for participation in this study. *Objects of the study*—30 patients (13 men and 17 women aged 28 to 57 years) with included defects of tooth alignment of various location and extent, with indications and intentions for prosthetic treatment with the use of DI. Monitoring groups for the comparative placebo-controlled trial were formed by the method of restricted randomization: *the laser group* (7 men and 8 women aged 31 to 54 years)—LG, the patients in the complex of dental implantation received “active” LLLT, generating the corresponding laser radiation by B-Cure Laser Dental Pro device, and *the placebo group* (6 men and 9 women aged from 28 to 57 years)—PG, the patients received “inactive” placebo B-Cure Laser Dental Pro device with an identical exterior design and handling characteristics, simulating the generation of LLLT and with specific, understandable only by the dentist encoding.

The patients of LG used a portable laser therapeutic dental devices B-Cure Laser Dental Pro (Good Energies®, Israel)—Ga-Al-As diode laser generated infrared laser radiation (wavelength—808 nm, power—250 mW, pulse frequency—14 kHz) with unfocused beam 4.5 cm × 1.0 cm with a power density of 14.4 J/min at the peak (3.2 J/cm² per minute). The device has the necessary international certificates (CE 0120—Medical Device), approved for the use in the field of healthcare.

At the baseline (T₀), on the 2–3 (T₂₋₃), 5–7 (T₅₋₇), 10–14 (T₁₀₋₁₄) days and 3 months (T₉₀) after the operation of DI the structure, the frequency and severity of complications in early and late postoperative period were analyzed in the patients: pain symptom – PS, including the combination with edema and inflammation (swelling-pain symptom—SPS); general (fever, enlargement of regional lymph nodes, etc.) and/or local inflammatory reactions of the oral mucosa (OM) in the area of DI and its perifocal areas (edema, hyperemia, presence of plaque), “peri-implant mucositis”; fascial edema; postoperative hematomas; abscesses; divergence of the edges and/or bleeding of wounds; neurological disorders (hyper-, hypo- or paresthesias, neuralgia) in the maxillofacial area; taste disorders; halitosis.

Identified PS was characterized by the prevalence, the character (intensity, duration, localization) and the effect on “pain behavior,” including for the needs of pain relief with analgesics. The author’s technique of PS assessment based on the modified color-numeric visual analogue scale (RP No. 2706 from 06.06.2016) was used for the objectification of subjective feelings of PS intensity. The color-digital codes were: 0 ≤ VAS < 3 (“cold” violet-blue color codes)—mild PS; 3 ≤ VAS < 7 (green-yellow color codes)—moderate PS; 7 ≤ VAS < 10 (“warm” orange “hot” red color code)—severe PS; VAS = 10 (“hot” red color code)—insufferable pain.

Integral (ΣOHIP-49-RU) and scale indicators of dental quality of life index “Oral Health Impact Profile” OHIP-49-RU (O.S. Gileva et al. 2009; RP No. 2435 from 22.02.2008) were evaluated in all points of observation (T₀, T₂₋₃, T₅₋₇, T₁₀₋₁₄, T₉₀).

According to the results of primary examination the patients of both groups were comparable by age-gender characteristics, levels of systemic and dental health safety, structure, clinical and topographical characteristics of dentition defects, the quality of the jaw bone (I-II type of bone according to Lekholm U. and Zarb G., D2-D3 by Misch C.E. et al.) and the level of quality of life reduction, which resulted in comparable approaches to the choice of DI technique and reconstructive plastic surgery, as well as modes of LLLT.

Photo shooting of the oral cavity was performed with the use of retractors and mirrors with the Canon EOS 600D (Japan) camera. Project, structure and research methodology was approved by the PSMU Local ethics committee. The significance of differences between compared values were estimated by parametric (Student’s t-test using N.A. Plokhinskii table for small samples) and nonparametric (calculation of exact F-Fisher criterion) methods using the STATISTICA 10 software.

The complex of LLLT using B-Cure Laser Dental Pro technology was carried out in “preventive” (at preoperative stage) and in “treatment mode” (at postoperative period) modes. LLLT in “preventive mode” were conducted by a trained dentist in the dental office using contact, stable technique, with radiation power of 250 mW, a pulse frequency of 14 kHz, unfocused beam area of 4.5 cm², transcutaneously in the projection of dentoalveolar segments corresponding to the DI installation location; a course of 2-3 procedures daily, with a duration of 8 min. LLLT in the “treatment mode” was carried out by a trained patient at home on the next day after the operation of DI by the following method: contact, stable, with the same parameters of wavelength (808 nm), power (250 mW), pulse frequency (14 kHz) and area of irradiation (4.5 cm²) of the skin in the projection of the dentoalveolar segment(s) corresponding to the area of DI. The sessions of laser therapy (2) were carried out after the operation on a daily basis, lasting for 8 min (total exposure time—16 min.), the course—7–10 days.

Optional LLLT was carried out by the patient at the stage of gingival formation using contact, stable technique, transcutaneously in the projection of DI: daily, duration of the procedure—8 min, treatment course—3–5 procedures.

RESULTS AND DISCUSSION

Clinical efficacy of LLLT in complex of DI was analyzed in a comparative perspective (DI + LLLT; DI + LLLT-placebo) from the standpoint of prevention and effective relief of early and late complications of the postoperative period, and ensure complete osseointegration of implants with optimized periimplantation gingival attachment.

The severity (magnitude), the structure and duration of the pain symptom in the patients of compared groups in the postoperative period is shown in Fig. 1.

The pain symptom in the patients of PG was detected most often (93.3%) 2–3 days (T₂₋₃) after surgery, and in 66.6% of patients its magnitude was shifted towards a moderate and severe symptoms (3 < VAS < 10). By 5–7 days (T₅₋₇) of postoperative period, the detection rate of PS decreased by 28.5%, weakly expressed forms (0 < VAS < 3) dominated (60.0%) in its structure. After 10–14 days (T₁₀₋₁₄) in 13.3% of the patients mild PS (0 < VAS < 3) remained. In one patient the pain in the area of DI, radiating along the branches of the trigeminal nerve was preserved for a week after implant placement. Half (53.3%) of the patients of PG with moderate PS to 2–3 days of the postoperative period changed their “pain” behavior at the expense of analgesics, restriction of loads, changing of eating behavior; 26.7% of the patients with persistent PS continued to receive pain medications till the 5th day of the postoperative period.

The pain symptom in the patients of LG was also the most significant in the prevalence and clinical manifestation at 2–3 days (T₂₋₃) after surgery. However, the frequency of detection at this point (26.7%) was significantly ($p < 0.01$) lower than in PG, but the magnitude of the pain was shifted toward mild forms (0 ≤ VAS < 3). PS was observed only in 2 patients and was manifested only in the light form one week (T₅₋₇) after the operation. None of the patients after the home use of B-Cure Laser Dental Pro device felt the need to use the analgesics.

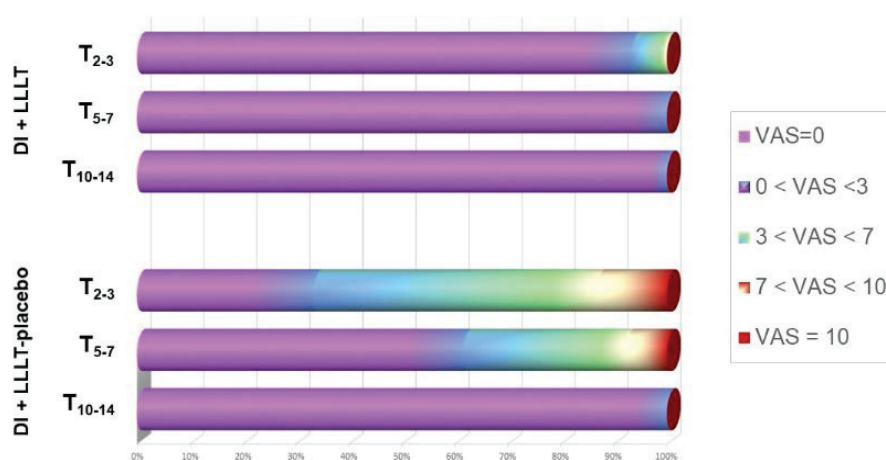


FIGURE 1. The magnitude of pain (VAS scores) and the restructuring of the pain symptom in patients of compared groups in postoperative period of dental implantation stages (T₂₋₃–T₁₀₋₁₄)

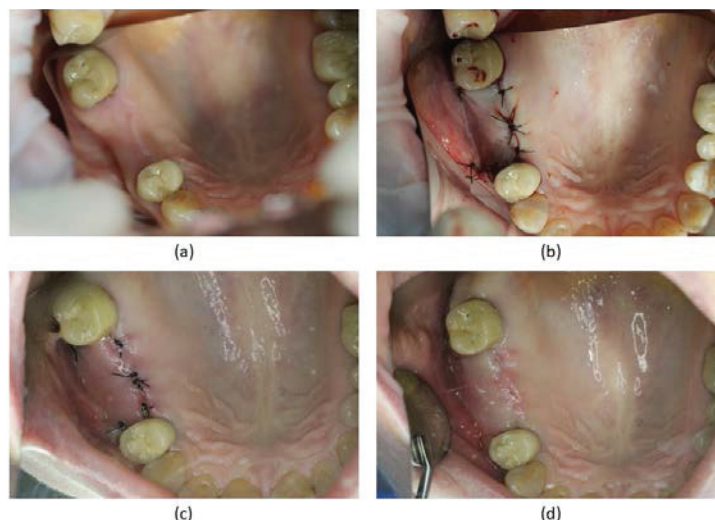


FIGURE 2. Patient C., 41 years old (laser group). The lack of 1.6., 1.7 teeth; (a) LLLT was conducted in a preventive mode, the state of DI area before surgery; (b) the state after the operation (T_1)—wound after DI with simultaneous sinuslift; (c) LLLT was conducted in the treatment mode: the 3rd day after the surgery—slight swelling and redness of periimplantation tissues; (d) good condition of periimplantation tissues after removal of sutures

Two thirds (66.7%) of the patients in PG noted local inflammation (swelling, redness) in the area of implantation, mostly slightly or moderately expressed (respectively 33.3% and 26.7%) in 2–3 days (T_{2-3}) of postoperative period. The detection rate of local inflammation decreased (in 2.5 times) significantly on T_{5-7} . The phenomenon of local inflammation in 73.5% of cases was combined with weak or moderately strong fascial edema with asymmetry of the face. Moderate edema of soft tissues was preserved only in one patient of PG at T_{5-7} .

The inclusion of LLLT in complex of preoperative preparation and postoperative management of the patients of LG ensured the prevention of local edema and inflammatory complications in the area of DI (Fig. 2) and fascial edema in 80.0% of cases. The symptoms of local, mainly slight, inflammation, in periimplantation area were revealed (Fig. 2) only in 20.0% of the patients at T_{2-3} , i.e. 3.3 times less than in PG. Swelling of the soft tissues of the face at this period was manifested in the patients of LG 3.7 times less than in PG. By the 5th day after DI local inflammatory manifestations were not observed in any of the patients.

The frequency of occurrence of oral mucosal postoperative hematomas on T_{2-3} in the patients of PG was significantly ($p < 0.05$) higher than in the patients of LG, (33.3% versus 13.3%, respectively), including the vast, exciting area of 1-2 jaw segments and adjacent areas of oral mucosa and lips (Fig. 3), often continuing for 5 days after surgery.

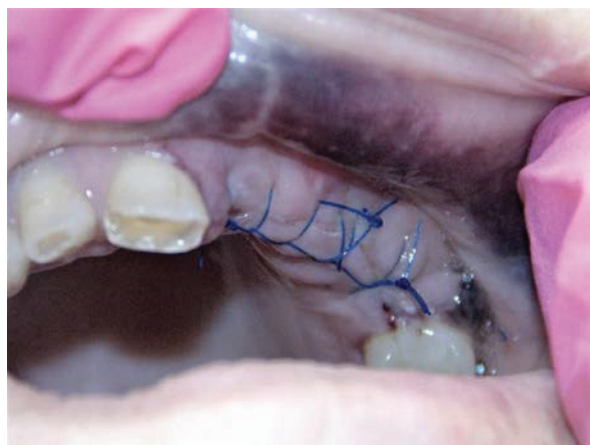

FIGURE 3. Patient I., 57 years (placebo group). The lack of 1.6, 1.5, 1.4, 2.1, 2.2, 2.3, 2.4 teeth; the 3rd day after the surgery—a large hematoma of oral mucosa of the alveolar process and the upper lip

Only in the patients of PG (in 20.0% of cases) after DI on the lower jaw transient sensory-paresthetic symptom was noted. It was manifested by paresthesia of the chin, including 6.7% of observations in combination with the typical neurological pain, radiating in the course of the inferior alveolar nerve.

On T_{2-3} in the absolute majority of PG patients mouth opening was restricted in comparison with the initial values (29.32 ± 4.40 mm versus 45.50 ± 6.22 mm; $p < 0.05$); in isolated cases significant (up to 16.5 mm) difficulty in mouth opening was recorded that had persisted for a week after DI. Individuals of LG did not note the authentic restrictions in mouth opening that was observed neither in subjective feelings of patients, nor as an objective indicator as for T_{2-3} after surgery (32.51 ± 3.60 mm), and T_{5-7} (40.22 ± 2.53 mm) and T_{10-14} (44.17 ± 3.01 mm).

At baseline the patients of both groups with dentition defects revealed a comparable degree of dental quality of life reduction, primarily reflected by its psychological components (scale “Psychological discomfort” and “Psychological disorders”), and “Physical disorders”. On T_{2-3} (on the background of pronounced pain, swelling and inflammatory symptoms) in the patients of both groups the changes of integral indicators $\Sigma_{OHIP-49-RU}$ (115.2 ± 6.1 —in the LG and 135.9 ± 4.8 —in the PG) were recorded, that objectify the subjective feeling of the quality of life reduction on scales reflecting the degree of physical discomfort and dysfunctional disorders. On T_{10-14} intra-group results reflected the improvement of subjective feelings of the quality of life on the background of the relief of swelling and pain symptoms, more pronounced in the patients of LG (105.6 ± 4.3 versus 107.7 ± 4.8 , respectively). On T_{90} integral indicators $\Sigma_{OHIP-49-RU}$ in the compared groups were 82.1 ± 3.9 (LG) and 93.2 ± 4.3 (PG) that objectify the improvement of dental components of quality of life on the back of psycho-emotional status recovery in connection with the completion of the surgical stage of treatment and readiness for prosthetics.

CONCLUSION

The results of the study are consistent with the known data that DI in some cases can create problem situations for the doctor and the patient, manifested a steady and severe pain symptom, orofacial swelling, etc. The use of original LLLT techniques in prevention and treatment regimes before and after DI significantly (in 3.5 times) reduces the frequency and intensity of the pain symptom in the first days after the installation of endosseous implants, promotes earlier and more complete relief without additional analgesics within the first 5 days of the postoperative period in comparison with placebo-laser therapy. The inclusion of LLLT in DI complex by 3.3–3.7 times reduces the frequency, duration and intensity of local edema-inflammation in periimplantation area and edema of soft tissues, prevents the development of clinical functional and aesthetic disorders, associated with limitation of mouth opening throughout the surgical stage of DI. The data confirm the information that in some patients early postoperative DI may be accompanied by pronounced physical and psychological discomfort, pain symptom, functional and aesthetic disorders, manifested by a decrease in dental dimensions of quality of life. Effective relief of swelling pain and sensory-paresthetic symptoms as well as associated aesthetic, functional and psychological disorders on the background of LLLT allows minimizing subjective feelings of reduced quality of life in terms of $\Sigma_{OHIP-49-RU}$ in the early postoperative period. The results of the study indicate the possibility of expanding the indications for the use of defocused laser beam of B-Cure Laser Dental Pro device in the complex treatment of inflammatory diseases and oral mucosa, TMJ, endodontic and systemic neurological diseases, traumatic injuries of maxillofacial region, in these directions our research will be continued.

REFERENCES

1. O. S. Gileva, T. V. Libik, E. D. Nazukin, A. Yu. Yakov, and E. A. Gorodilova, *Stomatologiya Dlya Vsekh* **2**, 14–18 (2015).
2. A. A. Kulakov and R. Sh. Gvetadze, *Stomatologiya* **5**(2), 57 (2012).
3. J. Dolz, F. J. Silvestre, and J. Montero, *Int. J. Oral Maxillofac. Implants* **29**(2), 391–401 (2014).
4. *Emerging Trends in Oral Health Sciences and Dentistr*, edited by Mandeep Singh Viridi (InTech, 2015).
5. E. V. Goldshteyn, S. I. Kozitsina, and I. G. Gritsay, *Inst. Stomatol.* **4**(69), 105–107 (2015).
6. V. I. Semennikov, Yu. V. Teytelbaum, and A. V. Pantelev, *Bull. VSNC SO Russ. Acad. Med. Sci.* **4**, 98 (2012).
7. A. A. Timofeev, *Sovr. Stomatol.* **4**(78), 96 (2015).
8. J. Pi-Anfruns, *Alpha Omegan* **107**(1), 8–12 (2014).
9. I. D. Zinner, S. Markovits, C. E. Jansen, H. J. Shapiro, and P. E. Reid, *Gen Dent.* **58**(5), 416–422 (2010).
10. N. B. Korchazhkina, “Metodi fizioterapii v dentalnoy implantatsii,” D.M.D. thesis, Moscow, 2002.

11. S. V. Moskvina and A. N. Amirkhanyan, "Metodi kombinirovannoy I sochetannoy lazernoy terapii v stomatologii" (Moscow, 2011).
12. F. R. Rashidi, "Lechenie periimplantitov s ispolzovaniem nizkointensivnogo lazernogo sveta," Ph.D. thesis (Voronezh, 2009).
13. H. Chung, T. Dai, S. K. Sharma, Y. Y. Huang, J. D. Carroll, and M. R. Hamblin, [Ann. Biomed. Eng.](#) **40**(2), 516-533 (2012).
14. R. Fekrazad, N. Chiniforush, S. A. Bouraima, M. Valipour, M. Aslani, M. Zare, and O. A. Safari, *J. Lasers Med. Sci.* **3**(S.1, 4), 135–140 (2012).
15. J. M. Garcia-Morales, P. Tortamano-Neto, F. F. Todescan, J. C. de Andrade, Jr., J. Marotti, and D. M. Zezell, [Lasers Med. Sci.](#) **27**(4), 703–711 (2012).
16. M. Khadra, *Swed. Dent. J. Suppl.* **172**, 63 (2005).
17. H. Lalabonova, [J. IMAB Ann. Proc.](#) **17**(2), 104–106 (2011).
18. G. Romanos, [J. Ind. Soc. Periodontol.](#) **19**(5), 490–494 (2015).
19. P. Surendranath and R. Arjankumar, [IOSR J. Dental Med. Sci.](#) **12**(5), 56–59 (2013).
20. J. C. Prados-Frutos, J. Rodríguez-Molinero, M. Prados-Privado, J. H. Torres, and R. Rojo, [Lasers Med. Sci.](#) **31**(2), 383–392 (2016).
21. A. A. Vilisov, *Tomsk State Univ. J.* **285**, 148–154 (2005).
22. V. E. Prokopjev, "Biophizicheskie mekhanizmi vozdejstviya nizkointensivnogo lazernogo izlucheniya na biologicheskie tkani I opticheskie metodi diagnostiki ikh sostoyaniya," D.Ph-M.N. thesis, Tomsk, 2004.
23. C. Fornaini, A. Pelosi, V. Queirolo, P. Vescovi, and E. Merigo, [Laser Therapy](#) **24**(1), 47–52 (2015).